

## **SPHINCTEROPLASTY : TECHNIQUE AND RESULTS**

**Bruno ROCHE**

**Outpatient Clinic for Surgery**

**Unit for Proctology**

**University Hospital of Geneva**

**Tel: +41 22 3727934**

**Fax: +41 22 3727909**

**[Bruno.roche@hcuge.ch](mailto: Bruno.roche@hcuge.ch)**

**[www.proctology.ch](http://www.proctology.ch)**

## **Introduction**

To ensure normal continence it is necessary to have:

Normal anatomical structures

- Adequate rectal compliance
- Enough striated muscle with good contraction and low fatigability
- A smooth internal sphincter with normal function
- Conservation of the anorectal inhibitory reflex of Debray
- Unaltered medullary and cerebral reflexes
- Functional baroreceptors within levator muscles
- An adequate number of sensitive nerve endings within anal canal mucosa
- Anal cushions of normal size (not widely excised or hypertrophied)

Functional alteration or destruction of at least one of these conditions may result in more or less severe incontinence (11).

Aims of sphincteroplasty or reconstruction of the anal sphincter is to bridge a defect or tear of the muscular coating of the anal canal. Such a procedure can only correct the muscular component responsible for the development of fecal incontinence (5, 19).

Sphincter tears may result from obstetrical damage, surgery or trauma.

In our experience on 234 cases of sphincter tears operated we noticed following aetiologies:

---

	WOMEN	MEN
NB of cases	205	29
Obstetrical damage	171	
Surgery	25	11
Trauma	9	18

---

In women obstetrical (3) damage are responsible of 84 % of the lesions observed, surgery of 12 % and trauma of 4 %. In men 38 % of sphincter damage are due to surgery and 62 % to trauma

## **Preoperative investigations**

The recent development of endoanal sonography (15, 16) has allowed precise identification of previously unsuspected sphincter tears. This examination is useful to identify the number, site and size of sphincter tears. Results of these investigations allow to tailor the surgical procedure according to the sonography findings. Other investigations as manometry, PNTML measures, EMG are less important in decision making. Associated neurological damages should not prevent

from undertaking a sphincter reconstruction but may explain why results are not perfect in some cases.

### **Technical considerations**

Direct reconstruction is the procedure of choice for tears, traumatic and obstetrical laceration, or iatrogenic sphincter section. In fresh lesions, reconstruction with end-to-end sphincter suture should always be tried.

For old, established lesions secondary sphincteroplasty gives also good results.

Bowel preparation is not mandatory: we just ask the patient to pass stools and to come to theatre with an empty rectum. We prefer to remove solid stools left at the beginning of the procedure than to have a rectum still containing liquid stools, which may escape and contaminate the operative field during surgery.

Broad-spectrum perioperative antibiotics should be given.

A protective colostomy is only indicated in acute cases where sphincter tears are associated with fracture of the pelvis, with laceration or perforation of the rectum. This is never the case for obstetrical damage.

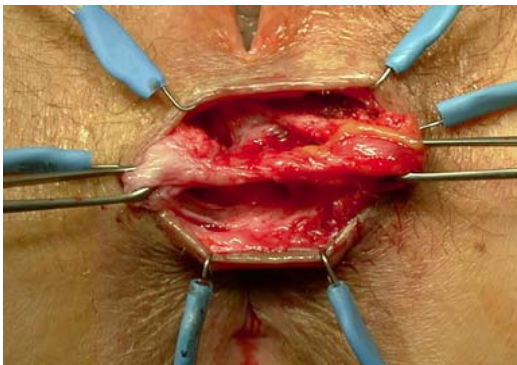
The patient is operated in lithotomy position with the buttocks protruding down the operative table.

The perineal skin is disinfected as well as the anal canal and the vagina. The patient is not shaved. The surgeon just removes by cutting the hairs around the incision line.

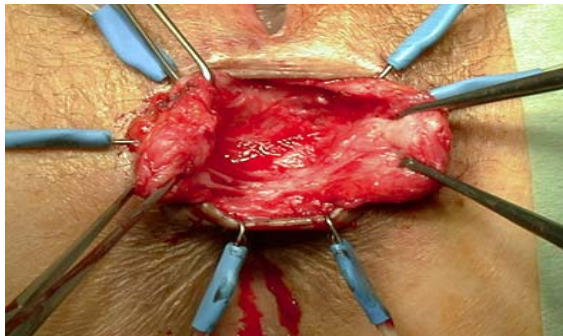
The perineum is infiltrated routinely with a solution containing a long lasting anaesthetic drug and a vasoconstrictor (ornithine-8-vasopressine : POR-8<sup>R</sup>) to achieve a bloodless operative field.

A curvilinear incision parallel to the external sphincter, extending at least 180° - 200° is performed. The anoderm and anal mucosa are mobilised from the scar and the underlying sphincter. Any skin perforation should be avoided. The sphincters are dissected free with a wide margin. We do not separate the internal from the external sphincter. As a proper plan of dissection may be difficult to identify, dissection is started at the normal muscle and continued into the scar. We don't need an electric stimulator, thanks to the ischemic blood field it is easy to differentiate the muscle from the different anatomical structures. The dissection is performed on all the length of the external sphincter up to the levators. If a narrow bridge of the external sphincter is still present, we routinely divide it to allow more extensive dissection.

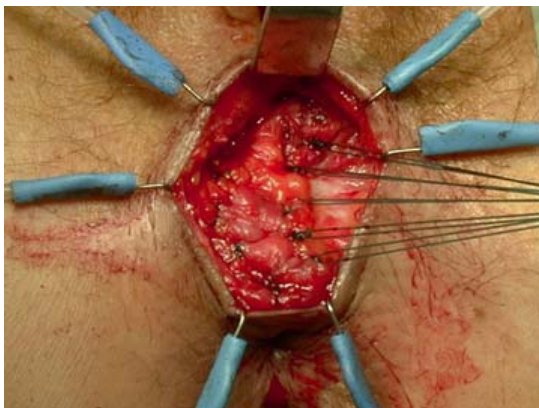
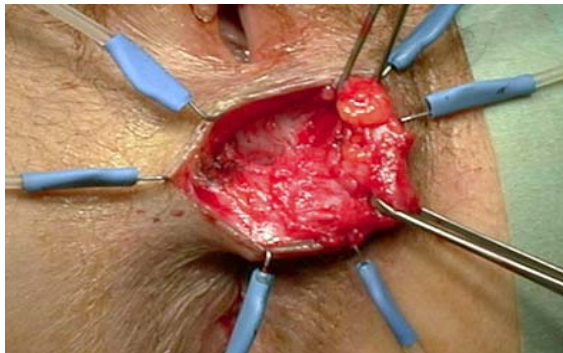
Nerve branches should be preserved.



Left bridges of sphincter should be divided.



Mobilisation of sphincter extremities



Overlapping

In case of post-obstetrical vaginal grade 3rd or 4 th tear, the mucosa and skin scars are excised; the anoderm and the vaginal mucosa are mobilised and opposed with 2-0 or 3-0 synthetic absorbable suture before any attempt at muscular repair

After mobilisation, muscle ends are overlapped to reduce the anal diameter and to increase healing between both edges. Fibrotic edges of the sphincter should not be excised. Double-U stitches should be placed using slowly absorbable synthetic monofilament, as Maxon or PDS OO. Knots should be tied carefully to avoid further muscular dilaceration, as healthy muscle is not able to hold a simple suture. During the procedure, the wound is frequently irrigated with saline to prevent bacteriological contamination.

Vaginal and anal wound edges are closed whereas skin edges are approximated to allow drainage and to prevent infection.

### **Postoperative care:**

The patient can take showers the day after surgery but should avoid long stays in water during 2 weeks. The suture line is disinfected 2 to 3 times per day and of course after each bowel movement. The wound is protected with a simple pad of gauze hold in place by a slip.

We don't restrict bowel movement any more. We order laxatives and paraffin oil from the day of surgery. As soon as the patient feels the need to pass stools, an enema should be given at any time, day and night, in order to have liquid stools passing without straining. Normal diet is continued; mucilage and bulk-forming agents are given together with paraffin oil for 2 to 3 weeks.

Physical training of the sphincter and biofeedback should not be encouraged before day 15 (8, 12). Thereafter the patient should three times a day contract and pull up his sphincters in direction of the umbilicus 10 to 20 times. Duration of contraction should be shorter than duration of relaxation in order to avoid any ischemia of the muscles. The patient should go on with this form of self-training life long.

### **Postoperative complications**

Postoperative complications are rare but may be severe:

- infection in up to 24 % of cases
- skin dehiscence
- persistent incontinence.
- sphincter suture leak

In our experience these complications may be prevented:

- wound should be irrigated and a single shot of broad-spectrum antibiotics should be given.
- skin sutures should be performed without tension with monofilament suture material.
- persistent incontinence may be due to two conditions: 1) inadequate or too short repair ; 2) underestimated associated pudendal nerve damage (6, 7, 20, 22, 25). Good preoperative evaluation and precise operative technique may prevent such a persistent condition.
- sphincter sutures leak may be caused by an over stretching due to the passage of hard and large stools. This can be prevented by the prescription of osmotic laxatives, paraffin oil and repeated enemas.

### **Early postoperative results**

Sphincteroplasty is successful in more than 90% of patients with faecal incontinence due to sphincter injury, restoring most of them almost completely to normal. Some published results are listed in next table.

Results of sphincteroplasty

Authors (year)	NB pts	Success (%)	Improved (%)
Fang (1984)(4)	76	82	89
Browning and Motson (1988)(2)	83	78	91
Yoshioka (1989)(24)	27	47	79
Wexner (1991)(23)	16	76	87.5
Arnaud and Sarles (1991)(1)	40	62.5	87.5
Londono-Schimmer (1994)(9)	94	50	75
Oliveira (1996)(13)	55	70.1	80
Gilliand (1998)(6)	100	55	69
Romano (2000)(18)	52	75	90.4
Marti and Roche (unpublished,17)	234	87	99

Results after obstetrical injuries seem to be better than after traumatic or postsurgical lesions ( 14,19 ).This may be partially due to the fact that trauma may interrupt normal connections

between internal and external sphincter, may destroy part of the musculature and may also result in nerve lesions.

In opposition to some published series, we didn't observe any difference in the postoperative results between young and old patients: patients below 62 years and patients over 62 years show the same postoperative improvement in their scores. There is therefore no reason not to perform a sphincter reconstruction in old patients with long-lasting traumatic sphincter tears (21, 17).

### **Late results.**

Several authors have noticed a deterioration of the results with time. Data from St'Marks hospital demonstrate that at 5 years only about 50 % of the patients are still improved (10). This worsening is attributed to the scar, to rupture of the reconstruction, to denervation and devascularisation linked to surgery and to ageing. In a retrospective study of 93 cases operated by only 2 surgeons, Roche could demonstrate that at five years 75 % are still improved (17). Furthermore some patient even improve their score on long term. The only parameter which could explain this improvement is that these patients were submitted postoperatively to muscular training by physiotherapy and biofeedback. They continue there training at regular interval and were conscious that muscular training and exercise was important to keep a high quality result. According to these data we now routinely order physiotherapy postoperatively.

### **Conclusions :**

Sphincteroplasty is a safe procedure to repair sphincters' tears resulting from trauma, surgery or obstetric damage. Precise preoperative evaluation is mandatory . Meticulous surgery should be performed to be successful. Long term results are as good in young as in old patients with longlasting lesions. Biofeedback and muscular training should be ordered to obtain long term good results.

### **Bibliography :**

1. Arnaud A, Sarles JC, Sielezneff I and all (1991)  
Sphincter repair without overlapping for fecal incontinence.  
Dis Colon Rectum 34 :744-747
2. Browning GP, Motson RW (1984)  
Anal sphincter injury : management and results of Parks' sphincter repair.  
Ann Surg 99 :351-357
3. Engel AF, Kamm MA, Sultan AH, Bartram CI, Nicholls RJ (1994).

Anterior anal sphincter repair in patients with obstetric trauma.  
Br J Surg ;81 :1231-1234

4. Fang DT, Nivatvongs S, Vermuelen FD, Herman FN, Goldberg SM, Rothenberg DA (1984)  
Overlapping sphinctero-plasty for acquired anal incontinence.  
Dis Colon Rectum 27 :720-722.
5. Felt-Bersma RJF, Cuesta MA, Koorevarr M (1996)  
Anal sphincter repair improves anorectal function and endosonographic image. A prospective clinical study.  
Dis Colon Rectum 39 :878-885
6. Gilliland R, Altomare DF, Moreira H, Oliveira L, Gilliland J, Wexner SD (1998)  
Pudendal neuropathy is predictive of failure following anterior sphincteroplasty.  
Dis Colon Rectum 41 :1516-1522.
7. Jacobs PPM, Schjeuer O, Kuijpers JHC, Viengerhoets MH (1990)  
Obstetric incontinence. Role of pelvic floor denervation and results of delayed sphincter repair.  
Dis Colon Rectum 33 :494-497.
8. Jensen LL, Lowry AC (1997)  
Biofeedback improves functional outcome after sphincteroplasty.  
Dis Colon Rectum 40 :197-200.
9. Londono-Schimmer EE, Garcia-Duperly R, Nicholls RJ, Ritchie JK, Hawley PR, Thomson JP (1994)  
Overlapping anal sphincter repair for fecal incontinence due to sphincter trauma : five years follow-up functional results.  
Int J Colorectal Dis 9 :110-113
10. Malouf AJ, Norton CS, Engel AF, Nicholls RJ, Kamm MA (2000)  
Longterm results of overlapping anterior anal sphincter repair for obstetric trauma.  
Lancet 355 :260-265
11. Marti M-C, Givel J-C  
Surgical management of anorectal and colonic diseases. 2<sup>nd</sup> edition  
Ed. M.-C. Marti et J.-C. Givel.  
Springer Verlag, Berlin (1998).
12. Norton C, Kamm MA (1999)  
Outcome of biofeedback for faecal incontinence.  
Br J Surg 86 :1159-1163
13. Oliveira L, Pfeifer J, Wexner SD (1996).  
Physiological and clinical outcome of anterior sphincteroplasty.



Br J Surg ; 83 :502-505.

14. Roche B, Michel JM, Deléaval J, Peter R, Marti MC (1998)  
Lésions traumatiques de l'anorectum.  
Swiss Surgery 4 :248-251
- 17 Roche B.(1998)  
Endorectal and anal sonography  
In : Marti M-C, Givel J-C  
Surgical management of anorectal and colonic diseases. 2<sup>nd</sup> edition  
Ed. M.-C. Marti et J.-C. Givel.  
Springer Verlag, Berlin (1998).
- 18 Roche B (2000)  
Evaluation de l'incontinence .  
in : Actualités proctologiques genevoises. Vol 1.  
Edit :M-C.Marti and B.Roche  
Pub. Médecine et Hygiène 2000.
- 17 Roche B.(2000)  
Approche diagnostique et thérapeutique de l'incontinence anale  
Thèse de Privat Docent . Faculté de médecine de l'Université de Genève.
18. Romano G, Belli G, Novi A, Esposito P, Farella A, Caggiano L (2000)  
Sphincteroplasties .p129-141  
In : Diagnosis and treatment of fecal incontinence  
Edit: G Romano.  
Pub. Idelson-Gnocchi , Napoli, p 347.
19. Sangalli,M and Marti, M-C. (1994)  
Anal sphincter repair for obstetrical tears.  
Am. J. Surgery. 179 :583-586
20. Sangwan YP, Collier JA, Barrett RC, Roberts PL, Murray JJ, Rusin L, Schoetz DJ  
(1996)  
Unilateral pudendal neuropathy . Impact on outcome of anal sphincter reappear.  
Dis Colon Rectum 39 :686-689.
21. Simmang G, Birnbaum EH, Kodner IR, Fry RD, Fleshman JW (1994)  
Anal sphincter reconstruction in the elderly :does advancing age affect outcome ?  
Dis Colon Rectum 37 :1065-1069
22. Tetzschner T, Sorensen M, Rasmussen O, Lose G, Christiansen J (1995)  
Pudendal nerve damage increases the risk of fecal incontinence in women with  
anal sphincter rupture after childbirth.  
Acta Obstet Gynecol Scand 74 :434-440

23. Wexner SD, Marchetti F, Jagelman DG (1991)  
The role of sphincteroplasty for fecal incontinence reevaluated : a prospective physiologic and functional review.  
Dis Colon Rectum 34 :22-30.
24. Yoshioka K, Keighley MRB (1989)  
Sphincter repair for fecal incontinence.  
Dis Colon Rectum 32 :39-42
25. Young CJ, Mathur MN, Eyers M, Solomon MJ (1998)  
Successful overlapping anal sphincter repair. Relationship to patient age, neuropathy and colostomy formation.  
Dis Colon Rectum 41 :344-349